

A Comparative Study of Functional Outcome Between Expert Tibial Nailing and Conventional IMIL Nailing for Proximal and Distal Tibial Fractures in Adults

Dr. S K Venkatesh Gupta¹, Dr. Prabhu B¹, Dr. Veer Abhishek Goud^{2*}, Dr. Sajeesh Shekhar²

¹Professor, Department of Orthopaedics, JJM Medical College, Davangere, Karnataka, India

²PostGraduate, Department of Orthopaedics, JJM Medical College, Davangere, Karnataka, India

*Corresponding Author: Dr. Veer Abhishek Goud, Department of Orthopaedics, JJM Medical College, Davangere, Karnataka, India.

Received: March 02, 2018; Published: March 08, 2018

Abstract

Aims: The aim of our study is to find the difference in the functional outcome between Expert tibial nailing and conventional Intra-Medullary Inter-Locking (IMIL) nailing for fractures of proximal 1/3rd and distal 1/3rd shaft of Tibia.

Materials and Methods: From July 2015 to September 2017, 100 patients with fractures of proximal 1/3rd and distal 1/3rd tibia out of which 50 were treated with conventional IMIL and 50 with expert tibial nailing in Bapuji and Chigateri General Hospital, Davangere, Karnataka, India. Postoperative treatment was same in both groups. They were followed up regularly until clinical and radiological union. Later, the functional outcome was assessed by using Klemm and Borner criteria.

Results: According to Klemm and Borner functional results, 60% in conventional IMIL group had excellent results, 20% had good results, 8% had fair results and 12% had poor results. Where as in the expert tibial nailing group, 68% had excellent results, 20% had well, 8% had fair and 4% had poor results.

Conclusion: Metaphyseal fractures are more difficult to treat but with newer nail designs like expert tibial nail, which allows proximal and distal segment to be controlled through placement of multiple angulated proximal and distal interlocking screws within a small distance. This mechanism is lacking in the conventional IMIL nail showing the superiority of expert tibial nail on treating metaphyseal fractures.

Keywords: Expert nail; Metaphyseal; Intramedullary interlocking nailing; Conventional IMIL

Volume 2 Issue 1 March 2018

© All Copy Rights Reserved by S K Venkatesh Gupta, *et al.*

Introduction

As industrialization and urbanization are progressing year by year with rapid increase in traffic, incidence of high energy trauma is increasing with the same speed. The tibia is the most commonly fractured long bone, because the exposed anatomical location of the tibia makes it vulnerable to the direct blow and high energy trauma. In contrast to the rest of appendicular skeleton, distal tibia has precarious blood supplies due to inadequate muscular envelope. The presence of hinge joints at knee and ankle, allows no adjustment for rotatory deformity after union of fracture. The optimum method of treatment remains a subject of controversy.

Citation: S K Venkatesh Gupta, *et al.* "A Comparative Study of Functional Outcome Between Expert Tibial Nailing and Conventional IMIL Nailing for Proximal and Distal Tibial Fractures in Adults". *Orthopaedic Surgery and Traumatology* 2.1 (2018): 269-278.

Various modalities of treatment such as conservative gentle manipulation and use of short leg or long leg cast, open reduction and internal fixation with plates and screws, intramedullary fixation and external fixation are known to treat tibia fractures. Open reduction and internal fixation with plates & screws has yielded unacceptably high rates of infection [1-3]. Surgeon should be capable of using all these techniques and must weigh advantages and disadvantages of each one and adapt the best possible treatment.

The intramedullary nailing, locked or unlocked has become an attractive option since image intensifiers has made closed intramedullary nailing possible. Nail is a load sharing device and is stiff to both axial and torsional forces. Intramedullary nails such as Lotles and Enders nails, used without reaming have been employed successfully. They are however contra-indicated for comminuted fractures, as there tends to be shortening, or displacement of such fractures around these small nails.

It preserves soft tissue sleeve around fracture site allows early motion of adjacent joints, locking of nails proximally and distally provides control of length, alignment and rotations in unstable fractures [4]. Closed nailing involves least disturbance of soft tissue, fracture hematoma and natural process of bone healing as compared to other forms of internal fixation.

Expert tibial nail is a newer implant that overcomes the problems encountered by the conventional nails. Several technical modifications compared to standard tibial nails are incorporated in the design of Expert tibial nail. The multiplanar locking options at the proximal and distal end allow for secure stabilization of metaphyseal fragments. The end cap achieves angular stability between the proximal oblique screw and the nail. These changes in implant design enhance the stability of the bone-nail construct and reduce the risk for secondary malalignment. This new system has been regarded as technically mature. It offers numerous locking options and has proven to worth in complex fracture situations.

Materials and Methods

From July 2015 to September 2017 in Bapuji and Chigateri General Hospital, Davangere. 100 patients with fractures of proximal and distal 1/3rd shaft of tibia, out of which 50 cases were treated with conventional Intra-Medullary Inter-Locking (IMIL) and 50 cases with expert tibial nailing. Adult patients above 18 years of age with proximal and distal tibial fractures are included in this study. We excluded patients with less than 18 years of age, Gustillo-Anderson compound type 3 and associated head and neurovascular injury.

All patients had plain radiographs and fractures were classified according to AO/OTA classification of fracture of proximal and distal tibia. The patients were taken for surgery after routine investigation and after obtaining fitness for surgery. Postoperative treatment was same in both groups. They were followed up regularly and until clinical and radiological union. Later, the functional outcome was assessed by using Klemm and Borner criteria.

Surgical Technique

All patients were operated under spinal anesthesia, with patient supine on the radiolucent table. The injured leg was positioned freely, with knee flexed 90° over the edge of operating table to relax the gastro soleus muscle and allow traction by gravity.

In all cases vertical patellar tendon splitting incision used. Next step is to determine the point of insertion. In the A.P view the entry point is in line with the axis of the intramedullary canal and with the lateral tubercle of the intercondylar eminence. In lateral view the entry point is at the ventral edge of the tibial plateau.

After selecting the point of insertion, curved bone awl is used to breach the proximal tibial cortex in a curved manner, so that from perpendicular position, its handle comes to be parallel to the tibial shaft. The ball tipped guide wire passed into the medullary canal of proximal fragment and the fracture fragments reduced under image intensifier by maintaining longitudinal traction in the line of tibia.

After reduction, the tip of ball tipped guide wire is adjusted to pass in the distal fragment up to 0.5-1 cm above the ankle joint under image intensifier. Medullary canal is then reamed starting from 8mm reamer size to 0.5 to 1 mm larger than the diameter measured using radiographs. Then the ball tipped guide wire is exchanged with smooth guide wire using the Teflon medullary tube. Next step is to pass an assembled nail into the medullary canal over the smooth guide wire.

In both the nailing system the nail with the provided proximal insertion handle and jig is passed over the guide wire and is inserted as far as possible, proximal end should be flush with the surface of cortex at the point of insertion. Routinely we prefer proximal locking first, but if gap is present at the fracture site we carried out distal locking first, which enables the use of the rebound technique or back slap technique to prevent distraction.

Distal locking using a by free hand technique with an image intensifier which provides a convenient method for targeting the distal locking holes. In conventional tibial nail, distally two media-lateral and one anteroposterior locking holes are present and in Expert tibial nail four distal locking holes are present two in medio-lateral plane, one in antero-posterior plane and one in oblique plane.

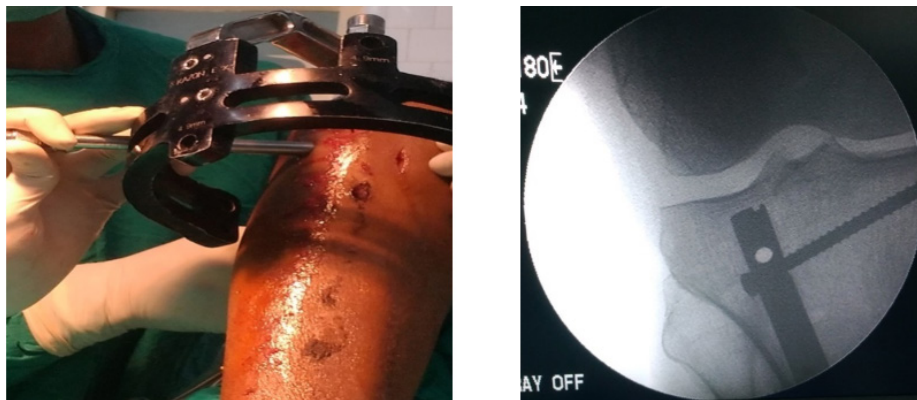


Figure 1: Proximal locking in expert Tibial nail.

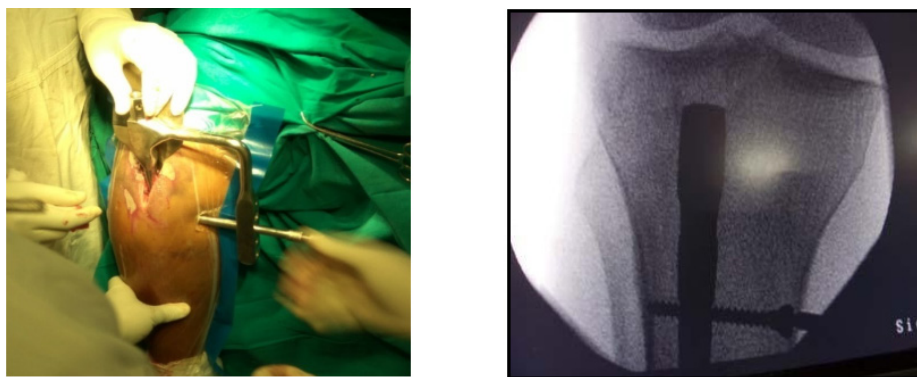


Figure 2: Proximal locking in conventional IMIL nail.

Results

Among the 50 patients treated with conventional IMIL, 33 were male and 17 were female. 26 patients in this group had right side involvement and 24 patients had left side involvement, of which 35 cases were of closed fractures, 10 cases were of open type-1 and 5 cases were open type-2.

Among the 50 patients treated with expert tibial nail, 31 were male and 19 were female. 27 patients in this group had left side involvement and 13 patients had right side involvement, of which 39 cases were of closed fractures, 7 cases were of open type-1 and 4 cases were open type-2.

In our study, 30 (60%) patients in the conventional IMIL group had solid union in less than 18 weeks, 6 (12%) cases had delayed union (> 20 weeks) and 2 (4%) cases ended up in nonunion. In two cases, nonunion was because of deep infection leading to loosening of implant before the fracture union. The Expert tibial nail group 44 (88%) cases had solid union in less than 18 weeks, 3 (6%) cases had delayed union and there was no case of nonunion.

Union	Group		Total
	Conventional IMIL (n = 50) n (%)	Expert Tibial Nailing (n = 50) n (%)	
12-14	12 (24)	24 (44.0)	36
16-18	18 (36)	20 (44.0)	38
19-20	12 (24)	3 (6.0)	15
>20	6 (12)	3 (6.0)	9
Non Union	2 (4)	0	2
Chi-Square Test, P Value = 0.138, Not Significant			
Mean	17.79	15.64	16.69

Table 1: Comparison of Union between 2 Study Groups (N = 100).

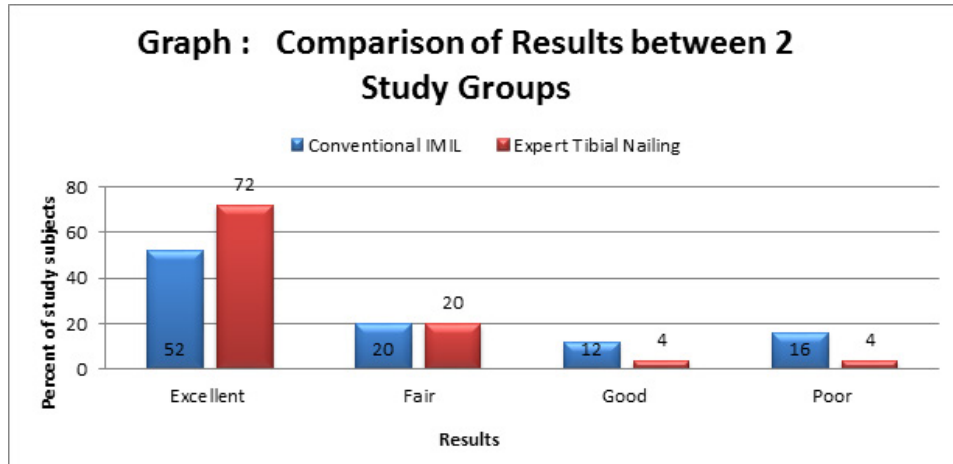
At 6 months follow up, results were assessed with Klem Borner criteria, it was seen that 26 (52%) patients in conventional IMIL group had excellent results, 10 (20%) patients had good results, 6 (12%) patients had fair results and 8 (16%) patients had poor results. Whereas in the expert tibial nailing group, 36 (72%) patients had excellent results, 10 (20%) patients had well, 2 (4%) patient had fair and 2 (4%) had poor results.

Results	Group		Total
	Conventional IMIL (n = 50) n (%)	Expert Tibial Nailing (n = 50) n (%)	
Excellent	26 (52.0)	36 (72.0)	62
Good	10 (20.0)	10 (20.0)	20
Fair	6 (12.0)	2 (4.0)	8
Poor	8 (16.0)	2 (4.0)	10
Chi-Square Test, P Value = 0.827, Not Significant			

Table 2: Comparison of Results between 2 Study Groups (N = 100).

Complications

In our study total of 11 cases of superficial infection were encountered, out of which 6 were in conventional IMIL group and 5 in expert tibial nail group. 6 cases developed deep infections, 3 in each group. 10 cases of delayed union of which 6 were in conventional IMIL group and 4 in expert tibial nail group, and 2 cases of nonunion which was seen in conventional IMIL group. 10 cases of malunion in which 7 were of conventional IMIL group and 3 of expert tibial nail group. 42 cases of anterior knee pain of which 22 cases of conventional IMIL group and 20 cases of expert tibial nail group, and 3 implant failure 2 in conventional IMIL group and 1 in expert tibial nail group.

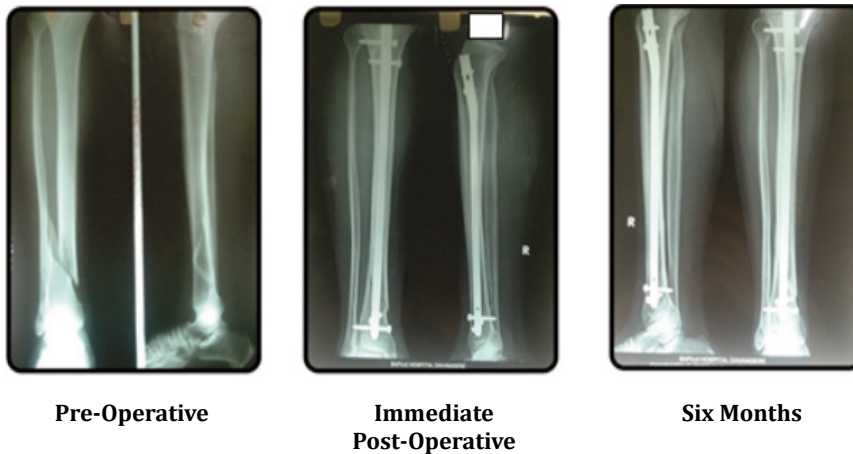


Complications	Group		Total
	Conventional IMIL (n = 50) n (%)	Expert Tibial Nailing (n = 50) n (%)	
Superficial Infection	6 (12.0)	5 (10.0)	11
Deep Infection	3 (6.0)	3 (6.0)	6
Delayed Union	6 (12.0)	4 (8.0)	10
Non Union	2 (4.0)	0 (0.0)	2
Mal Union	7(14.0)	3 (6.0)	10
Anterior Knee Pain	22(44.0)	20 (40.0)	42
Implant Failure	2 (4.0)	1 (2.0)	3

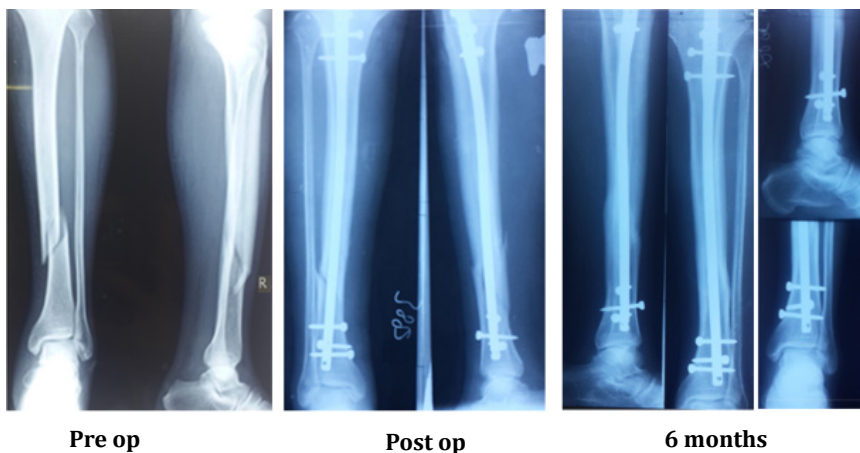
Chi-Square Test, P Value = 0.825, Not Significant

Distal 1/3rd Fracture

Conventional IMIL

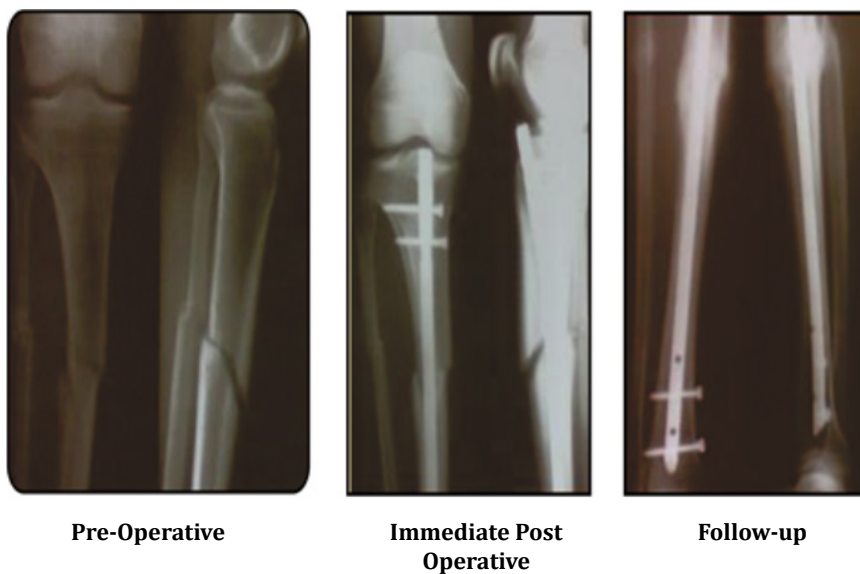


Expert Tibial Nail

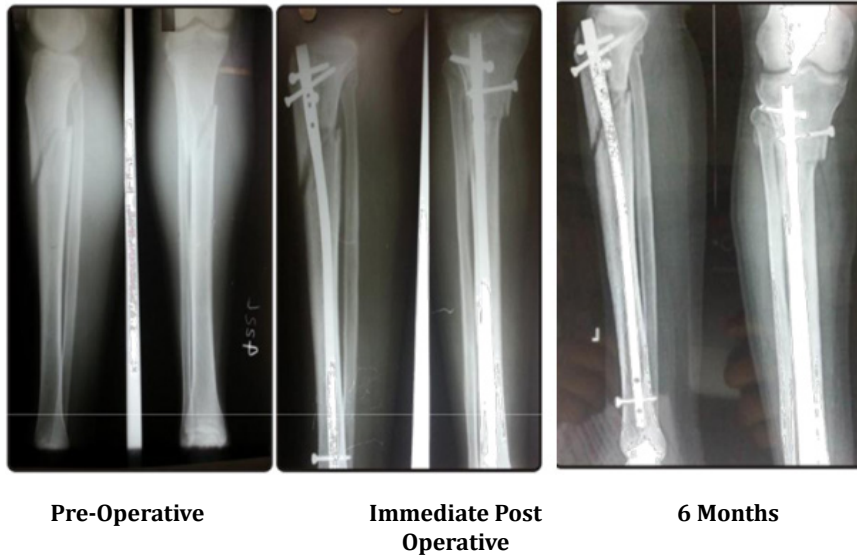


Proximal 1/3rd Tibia Fracture

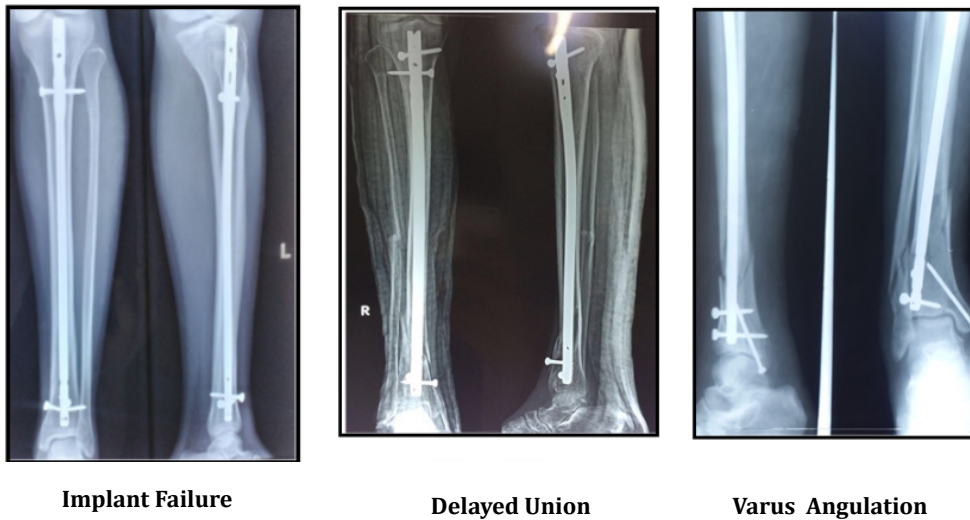
Conventional IMIL



Expert Tibial Nail



Conventional IMIL Nail Complication Ex pert Tibial Nail Complications



Discussion

There are several methods of treatments and many modifications in each treatment method. Closed reduction and cast application was practiced for many years based on Sarmiento functional cast bracing. But its main disadvantage was development of fracture disease.

Intramedullary nailing has many advantages. Closed reduction, reaming, inter-locking with bolts and screws all have advantages. Close reduction is also called as indirect reduction, it preserves fracture hematoma. Fracture unites by indirect healing. Chances of infection are very less in this method as soft tissue around fracture is undisturbed. Reaming prepares the canal into uniform diameter for proper fitting of nail. Interlocking with screws maintains axial length and rotation of fracture fragments.

The average age of all cases in this series was 41.35 years. The fracture is more common in the age group of 31-40 years in conventional IMIL group and 41-50 years in expert tibial nail group. Arne Ekeland, *et al.* [5] (1988), in a study series of 45 patients noted the average age of patients to be around 35 years. Court Brown, *et al.* [6] (1990), noted the average age to be 32.4 years. The increased incidence of open tibial fractures in young males corresponds with their activity level whereas the incidence again increases in elderly individuals due to osteoporosis⁴²

There were 64 male and 36 female patients showing male predominance in our series. Bread-Winning working men with outdoor activities are majority. Court Brown, *et al.* [6] (1990), in their series noted the male incidence to be round 81.3%, while the female incidence to be around 18.7%. Hooper, *et al.* [7] (1991), noted male incidence at 82% and female incidence at 18%.

In the present study, 74 cases are closed fractures. There were total 17 open type 1 and 9 open type 2 tibial fractures. There was no significant difference in healing with both closed & open fractures fixed with IMIL and expert tibial nailing.

Full weight bearing in our series was started at average of 14th week in conventional IMIL group and average of 10th week in patients of expert tibial nail group. Because of multiple angled locking system, stability of fixation was good and hence, weight bearing was started earlier. The appearance of bridging callus was used to assess and allow the patient full weight bearing.

Grosse and Kempf [8] (1991), allowed full weight bearing at 8.5 weeks. Larsen, *et al.* [10] allowed partial weight bearing of 15 kgs for 6 weeks in early post-operative period. The mean interval of the radiological union in the present study in conventional IMIL group was 17.79 weeks and in expert tibial nail group it was 15.64 weeks. Closed fractures and type 1 fractures united earlier compared to type 2 open fractures

Studies	Union time
Lahkpat, <i>et al.</i> [9]	16.8 weeks
A Mahmood [11]	14 weeks
Nandakumar [12]	15 weeks
Present study	
(conventional IMIL)	17.79 weeks
Present study (expert tibial nail)	15.64 weeks

In our study total of 11 cases of superficial infection where encountered, out of which 6 (12%) are of conventional group and 5 (10%) of expert tibial nail group, 6 (12%) deep infection in which 3 (6%) of each group, all infected cases were controlled with a short course of antibiotic treatment except for 2 cases which ended up in implant loosening and nonunion. Implant removal with medullary cavity excision by reaming and inserting wider diameter antibiotic coated PMMA nail was done. 10 (20%) delayed union of which 6 (12%) where of conventional IMIL group and 4 (8%) of expert tibial nail group. 10 (20%) malunion of which 7 (14%) where of conventional IMIL group and 3 (6%) of expert tibial nail group, 42 cases of anterior knee pain of which 22 (44%) cases of conventional IMIL group and 20 (40%) cases of expert tibial nail group, and 3 (6%) implant failure 2 (4%) in conventional IMIL group and 1 (2%) in expert tibial nail group.

Lakhpat Yadav, *et al.* [9] reported Complications restricted ankle movements in 3 patients, restricted knee movements in 2 patients, valgus at ankle seen in 2 patients, anterior knee pain in 2 patients, delayed union seen in 2 patients. In our study with conventional IMIL nail 7 (14%) cases of malunion was found, 4 with anteroposterior angulation and 3 with valgus angulation. Of these cases, two cases had 15°, one case had 10° and one with 5° of anteroposterior angulation in the fracture of proximal one-third of tibia close to the tibial tubercle, and only a single locking bolt could be inserted in these cases which could not hold the fracture in alignment.

In expert tibial nailing group, there were 3 cases of malunion with 1 case showing less than 5° valgus angulation, one showing 5° valgus angulation in distal third fractures and one shows 15° of anteroposterior angulation in proximal third fractures. None of the patients had any functional disturbance and cosmetic deformity, so no surgical intervention was done. We used a patellar tendon splitting approach in all the 10° patients, knee pain was found in 44% patients in conventional IMIL group and 40% patients in expert tibial nail group with kneeling activities.

Functional results were graded according to the criteria by Klemm and Borner [13] (1986). 52% of patients achieved excellent results, 20% of patients achieved good results, 12% showed fair results and 16% showed poor results in conventional IMIL group. In expert tibial nail group 72% showed excellent results, 20% showed good, 4% showed fair and 4% showed poor results.

Conclusion

- Intramedullary nailing is a safe and effective technique for treatment of metaphyseal fractures.
- The proximal and distal segment of these fractures are more difficult to control with intramedullary implants because of the metaphyseal flare.
- Tibial nailing may simultaneously address all proximal fracture, non-contiguous fractures and distal fractures.
- Newer nail designs like Expert tibial nail allows proximal and distal segment to be controlled through placement of multiple angulated proximal and distal interlocking screws within a small distance. This mechanism is lagging in the conventional IMIL nail, showing the superiority of Expert tibial nail on treating proximal and distal tibial fractures.
- Complications such as failure of bone-implant construct or post-operative malalignment are avoidable if careful pre-operative planning is allied with meticulous surgical technique.

Conflict of interest

No any financial interest or any conflict of interest exists.

References

1. Nicoll EA. "Fractures of the tibial shaft: A survey of 705 cases". *The Journal of Bone and Joint Surgery* 46 (1964): 373-387.
2. Brown PW and Urban JG. "Early weight bearing treatment of fractures of the tibia. An end result of 63 cases". *The Journal of Bone and Joint Surgery* 51 (1969): 59-75.
3. Bach AW and Hansen Jr ST. "Plates versus external fixation in severe open tibia shaft fractures. A randomized study". *Clinical Orthopaedics and Related Research* 241 (1989): 89-94.
4. Paige A Whittle, George W Wood II. "Fractures of lower extremity. 10th ed In: Campbell's Operative Orthopaedics". Terry S Canale, ed. Philadelphia: Mosby, Elsevier 1(2008): 2754-2757.
5. Ekeland A., et al. "Interlocking Intramedullary nailing in the treatment of tibial fractures. A report of 45 cases". *Clinical Orthopaedics and Related Research* 231 (1988): 208-215.
6. Court Brown CM., et al. "Closed intramedullary tibial nailing. Its use in closed and type I open fractures". *Journal of Bone and Joint Surgery* 72.4 (1990): 605-611.
7. Hooper GJ., et al. "Conservative management or closed nailing for tibial shaft fractures, randomized prospective trial". *Journal of Bone and Joint Surgery* 73.1 (1991): 83-85.
8. Grosse AG Taglang and Kempf GK. "Locking System". *Howmedica* (1991): 28.
9. Lakhpat Yadav., et al. "Functional Outcome of Expert Tibial Intramedullary Nailing For Metaphyseal and Diaphyseal Fractures of Tibia". *IOSR Journal of Dental and Medical Sciences* 15. 7 (2016): 70-74.
10. Larsen LB., et al. "Should insertion of intramedullary nails for tibial fractures be with or without reaming? A prospective, randomized study with 3.8 years follow up". *Journal of Orthopaedic Trauma* 18 (2004):144-149.

Citation: S K Venkatesh Gupta., et al. "A Comparative Study of Functional Outcome Between Expert Tibial Nailing and Conventional IMIL Nailing for Proximal and Distal Tibial Fractures in Adults". *Orthopaedic Surgery and Traumatology* 2.1 (2018): 269-278.

11. A Mahmood, *et al.* "Outcome of expert tibial nailing for distal third tibial fractures". *Orthopaedic Proceedings* (2018):
12. Nandakumar Bhairi, *et al.* "Prospective Study of Surgical Management of Distal Tibial Fractures in Adults". *Journal of Trauma & Treatment* 6 (2017): 2.
13. Klemm KW and Borner M. "Interlocking nailing of complex fractures of femur and tibia". *Clinical Orthopaedics and Related Research* 212 (1986): 89-100.

Submit your next manuscript to Scientia Ricerca Open Access and benefit from:

- Prompt and fair double blinded peer review from experts
- Fast and efficient online submission
- Timely updates about your manuscript status
- Sharing Option: Social Networking Enabled
- Open access: articles available free online
- Global attainment for your research

Submit your manuscript at:

<https://scientiaricerca.com/submit-manuscript.php>