

Hydropic Degeneration of Placenta – An Unusual Clinical Presentation

Dr. SK Kathpalia^{1*}, Dr. Jayshree Kulkarni², Dr. Divya Punetha³ and Dr. Aparna Karan⁴

¹Professor, Obstetrics and Gynecology, Dr DY Patil Medical College, DY Patil Vidyapeeth, Pimpri 410028 India

²Lecturer, Obstetrics and Gynecology, Dr DY Patil Medical College, DY Patil Vidyapeeth, Pimpri

^{3,4}PG Resident, Obstetrics and Gynecology, Dr DY Patil Medical College, DY Patil Vidyapeeth, Pimpri

***Corresponding Author:** Dr. SK Kathpalia, Professor, Obstetrics and Gynecology, Dr DY Patil Medical College, DY Patil Vidyapeeth, Pimpri 410028 India.

Received: April 19, 2018; **Published:** May 15, 2018

Abstract

Gestational trophoblastic neoplasms is a collective term for gestational trophoblastic diseases that invade locally or metastasize and include molar pregnancy, invasive mole, choriocarcinoma and placental site tumor. Molar pregnancy can be complete or partial; partial molar pregnancy can be confused with hydropic degeneration of placenta. This differentiation is required as follow up is different in both cases. We present a case where the fetal demise occurred in the first trimester but pregnancy continued and uterus reached much bigger size due to continuous placental proliferation along with hydropic degeneration.

Keywords: *Hydropic degeneration; Fetal demise; Hydatidiform*

Volume 2 Issue 2 May 2018

© All Copy Rights are Reserved by SK Kathpalia., *et al.*

Introduction

Gestational trophoblastic neoplasms (GTN) is a collective term for gestational trophoblastic diseases that invade locally or metastasize and the condition includes molar pregnancy (90%), invasive mole (5-8%), choriocarcinoma (1-2%) and placental site tumor (1-2%) [1]. Incidence of true molar pregnancy has been quoted as 1 in 400 to 1 in 1000, is more common in extremes of age [2,3]. Molar pregnancy can be complete or partial; partial molar pregnancy can be confused with hydropic degeneration of placenta.

This differentiation is required as follow up is different in both cases. Uterus is generally enlarged more than period of gestation in molar pregnancy, whereas in hydropic degeneration the size is smaller as this is a kind of missed abortion. Clinical presentation of hydropic degeneration is like that of a missed abortion where the USG shows a picture which is similar to molar pregnancy. At times hydropic degeneration is diagnosed when the products of missed abortion or Retained Products of Conception (ROPC) are sent for histopathological examination (HPE). We present a case where the fetal demise occurred in the first trimester but pregnancy continued and uterus reached much bigger size due to continuous placental proliferation along with hydropic degeneration.

Case Report

21 years old primigravida, LMP – 29 Dec 2016, reported for antenatal booking on 11 Mar (10 weeks 2 days), examination and investigations done were all normal. Her blood group was O positive. Level 1 scan done on 13 Mar 2017 showed 9 weeks 4 days of fetus with

Citation: SK Kathpalia., *et al.* "Hydropic Degeneration of Placenta – An Unusual Clinical Presentation" *Gynaecology and Perinatology* 2.2 (2018): 239-241.

cardiac activity. She was prescribed standard antenatal medications. She complained of occasional nausea but no vomiting for which she was advised dietary modifications and antiemetic. She had gone out of station and returned after two months. While at home she had got herself examined from a local doctor, the details about that examination were not available. She came for review check up on 26 May; examination findings were normal except that fundal height was 24 weeks which was more than 20 weeks period of gestation.

Fetal parts were not clearly felt and fetal heart was not audible. Repeat USG showed large heterogeneous mass with multiple cystic lesions within, a malformed fetus of 9 weeks CRL with no cardiac activity noted; features suggestive of partial mole (Figure 1). On asking leading questions she mentioned that occasionally she had experienced brownish discharge. No ultrasound was done when she had shown herself at her home town. In view of clinical and ultrasound findings; a diagnosis of partial mole was made and she was posted for suction evacuation. Diagnosis of twin pregnancy with hydatidiform mole in one gestation was ruled out as first USG had not shown any multiple gestations. Pre evacuation cervical ripening was done with vaginal prostaglandins and suction evacuation performed.

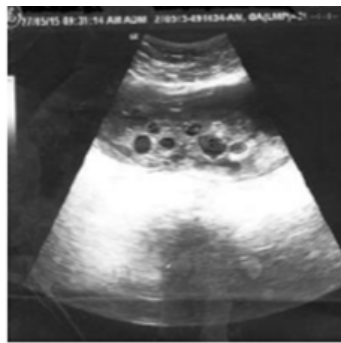

Figure 1: Ultrasound showing multiple cystic spaces along with malformed fetus.

There was excessive bleeding and she was transfused two packs of PRBC. The evacuated products showed some vesicles/grapes like tissue. Fetus could not be recognized in the evacuated products of conception. The tissue evacuated was sent for Karyotype and HPE. Blood for serum hCG was sent 48 hrs after evacuation for follow up, which turned out to be 1412mIU/mL. HPE did not show any molar tissue but it turned out to be hydropic degeneration (Figure 2), karyotype showed euploidy. Subsequent serum hCG done after a week was negative.

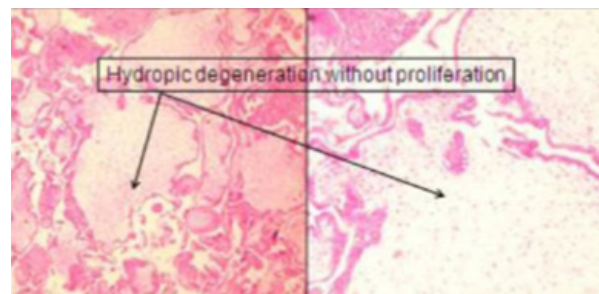


Figure 2: HPE (Simple hydropic degeneration).

Discussion

Hydropic degeneration of placenta is a harmless condition; is non-neoplastic in contrast to hydatidiform mole which is neoplastic and potentially malignant. These changes may be seen in certain conditions like simple hydropic degeneration which occurs in early fetal demise usually in first trimester, gestational trophoblastic diseases like partial mole, paternal triploidy and Beckwith Wiedemann

syndrome. Ultrasound appearance in failing pregnancy with hydropic degeneration depends on degree of vascular changes, necrosis, hemorrhage and breakdown of products of conception; which may mimic partial mole hence confused with it.

Sometimes differentiation is not possible on USG [4,5] and has to be confirmed by histopathology or genetic studies. Immunostains for p57KIP2 protein, a cyclin-dependent kinase inhibitor, can assist in distinguishing diploid complete moles from diploid spontaneous hydropic abortions and triploid partial moles.6 Partial moles are characterized by triploid karyotype of both maternal and paternal origin and the presence of fetal/embryonic tissue.

Conclusion

Hydropic degeneration is a common placental change which is usually seen in failed or failing pregnancies. The size of uterus is smaller than period of gestation in contrast to hydatidiform mole where the size is much bigger in most cases. The size of uterus was much bigger in our case which is an unusual finding. Hydropic degeneration cases do not need follow up after evacuation and this is neither malignant or has potential for malignancy.

Disclosure

Authors have none to declare.

References

1. Alireza A., *et al.* "Frequency of Molar Pregnancies in Health Care Centers of Tehran, Iran". *Journal of Reproduction & Infertility* 15.3 (2014): 157-160.
2. Savage P., *et al.* "The demographics of molar pregnancies in England and Wales from 2000-2009". *The Journal of Reproductive Medicine* 55.7-8 (2010): 341-345.
3. Madhuri S. "Hydatidiform mole: A sour encounter with a grapy case". *Indian Journal of Anaesthesia* 55.2 (2011): 171-173.
4. Anthony J Buschi., *et al.* "Hydropic degeneration of the placenta simulating hydatidiform mole". *Journal of Clinical Ultrasound* 7.1 (2005): 60-61.
5. Repiska V., *et al.* "DNA analysis in gestational trophoblastic disease". *Ceska Gynekologie* 68.6 (2003): 442-448.
6. Natalie B., *et al.* "Characteristics of hydatidiform moles: analysis of a prospective series with p57 immunohistochemistry and molecular genotyping". *Modern Pathology* 27.2 (2014): 238-254.

Submit your next manuscript to Scientia Ricerca Open Access and benefit from:

- Prompt and fair double blinded peer review from experts
- Fast and efficient online submission
- Timely updates about your manuscript status
- Sharing Option: Social Networking Enabled
- Open access: articles available free online
- Global attainment for your research

Submit your manuscript at:

<https://scientiaricerca.com/submit-manuscript.php>