

## Ultrasonography as a Diagnostic Tool for Salivary Gland Disorders

Nanan Nur'aeny\* and Riani Setiadhi

Oral Medicine Department, Faculty of Dentistry Universitas Padjadjaran, Bandung-Indonesia

\***Corresponding Author:** Nanan Nur'aeny, Oral Medicine Department, Faculty of Dentistry Universitas Padjadjaran, Bandung-Indonesia.

**Received:** January 01, 2018; **Published:** January 11, 2018

### Abstract

**Background:** Diagnosis of the patients with salivary gland disorders such as sialolithiasis (salivary stones), mucocele, ranula, and Sjogren's syndrome can be made based on symptoms, past and present medical history, clinical examination, and supporting examination such as salivary gland imaging. Ultrasonography as one of the salivary gland imaging that is noninvasive and cost-effective especially for biopsy guidance and mass detection.

**Purpose:** This paper will discuss about the use of ultrasonography in establishing the diagnosis of salivary gland disorders.

**Reviews:** An ultrasonography uses sound waves, the echoes of the sound waves create a picture of the inside of the body. The advantages of ultrasonography can be useful for parotid and submandibular gland disorders but has limited only for the superficial locations, but is best to differentiate between intra- and extra glandular masses, as well as between cystic and solid lesions. Solid benign lesions present as well-circumscribed hypo echoic intra glandular masses. Ultrasonography can also demonstrate the presence of an abscess in an acute inflamed gland, as well as sialolithiasis with echogenic densities that shows acoustic shadowing.

**Conclusion:** There are many salivary gland imaging that can be used to help in making the diagnose of salivary gland disorder, but as a dentist we should consider to use the ultrasonography eventhough still widely unknown however its benefits are rewarding.

**Keywords:** Ultrasonography; Diagnosis; Salivary gland disorders

Volume 2 Issue 3 January 2018

© All Copy Rights are Reserved by Nanan Nur'aeny and Riani Setiadhi.

### Introduction

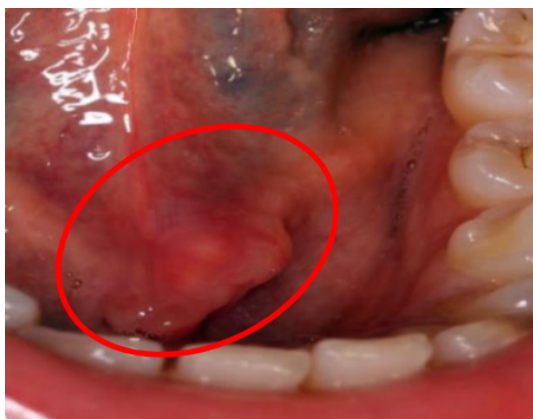
Diagnosis of the patients with salivary gland disorders such as sialolithiasis (salivary stones), mucocele, ranula, and Sjogren's syndrome can be made based on symptoms, past and present medical history, clinical examination, and supporting examination such as salivary gland imaging. There are two type of salivary gland imaging, radiation and non radiation imaging. Ultrasonography as one of salivary gland non radiation imaging that is noninvasive and cost-effective especially for biopsy guidance and mass detection. [1,2] The information about diagnostic tools in Dentistry especially for oral mucosal disease is still not much, so author will present the topic about the use of ultrasonography as a diagnostic tool for salivary gland disorders.

**Citation:** Nanan Nur'aeny and Riani Setiadhi. "Ultrasonography as a Diagnostic Tool for Salivary Gland Disorders". *Oral Health and Dentistry* 2.3 (2018): 393-397.

**Review**

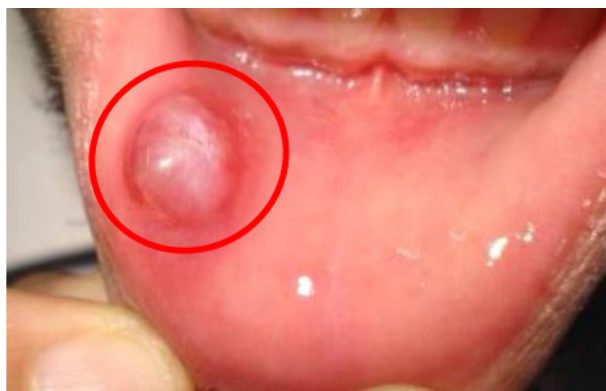In the early of 1950's, sonography was introduced in the Medical field. [3] USG uses high frequency sound waves (2-15 MHz) with wavelengths of 0,6-0,01 mm<sup>2</sup> If sound strikes the interface between media, the energy reflects as an echo. The echoes of the sound waves create a picture of the inside of the body. [3] USG is best to differentiate between intra- and extraglandular masses, as well as between cystic and solid lesions. [1,5] The disadvantages of USG are limited visibility of deeper portions of gland, the result depends on the operator's skill. [1,5]

Sialolithiasis ia a condition of obstructive disorders of salivary gland. [4] Ccalcified organic matter that forms within the secretory system of the major salivary glands. [1] The material forms a mucinous plug that is comprised of viscous glycoproteins, bacteria, and epithelial debris. [6] (Figure 1)



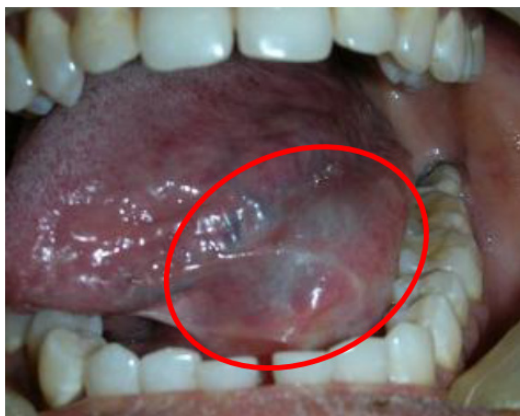**Figure 1:** Clinical presentation of a sialolith in left Warthon's duct. [7]

Mucocele is a swelling caused by pooling of saliva at the the site of injured minor salivary gland.4 Clinical feature of mucocele as a soft, fluctuant, and is walled-off by a rim of connective tissue yielding a cystic appearance. [4,5] most located on the lower lip (labial mucosa). [5] (Figure 2)



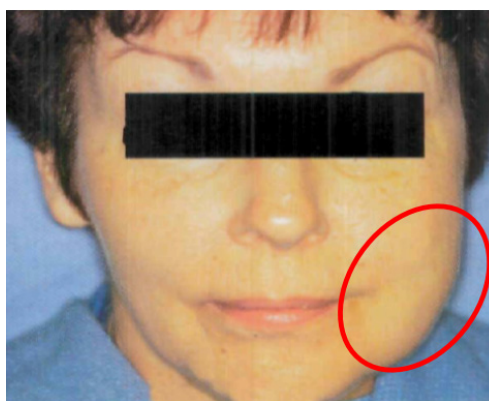**Figure 2:** Clinical presentation of a mucocele in lower right lip. [5]

Ranula is a large mucocele occuring in the floor of the mouth, in association with ducts of submandibular or sublingual glands. [4] Ranula can occur as congenital or acquired condition.9 There are two types of ranula i.e , superficial that associated with trauma of the sublingual glands, and plunging (ramifies deply into the neck). [4] (Figure 3)



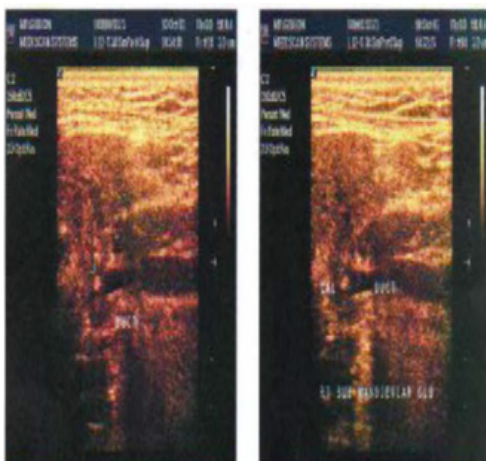
**Figure 3:** Clinical presentation of a ranula in left sublingual gland. [10]

Sjogren’s Syndrome (SS) is a chronic inflammatory disease that predominately affects salivary, lacrimal, and other exocrine glands. [4] SS classified as primary (without another autoimmune condition) and secondary (with the presence of connective tissue disorder. [1,11]

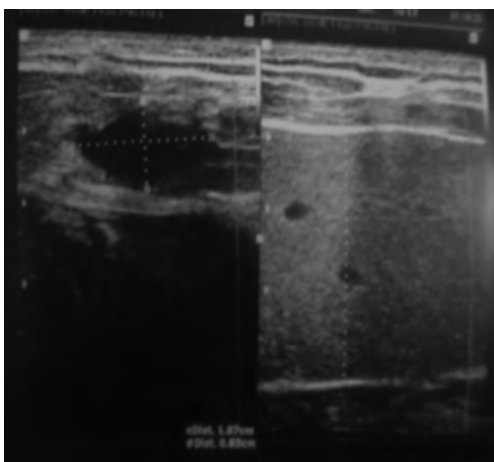


**Figure 4:** Clinical presentation of chronic unilateral parotid salivary gland enlargement in patient with Sjögren’s syndrome. [1]

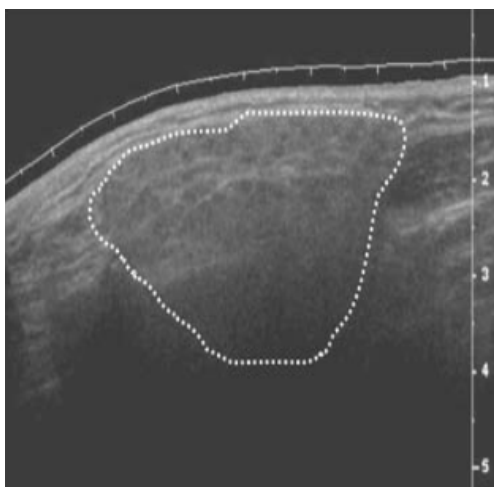
Salivary gland diseases are diverse ranging from the minor inflammatory conditions to a diverse group of benign and malignant neoplasms. [12] The value of Ultrasonography is well recognized in inflammatory soft tissue conditions of the head and neck region and superficial tissue disorders of the maxillofacial region. USG can provide the content of the lesion before any surgical procedure, both solid and cystic contents could be identified in USG. Sialoliths in parotid, submandibular and sublingual salivary glands can be detected by USG which appear as echo-dense spots with a characteristic of acoustic shadow. [3] (Figure 5) Mucocele and ranula also can be identified from USG imaging, it can revealed a space occupying mass, which was cyst like with capsule (Figure 6). It contained concentrated liquid. There was no blood vessel. The cyst was across the midline slightly and had a pressure effect on surrounding structures. From these findings, solid tumors such as pleomorphic adenoma and monomorphic adenoma could be rejected. [13] In Sjögren’s Syndrome the affected glands become less well defined, appear slightly darker (hypo echoic) than a normal gland, loose their uniform (homogenous) structure to show numerous, dark circular areas (Figure 7). The number and size of these dark areas appears to match the severity of the condition. Typically the foci vary in size but are usually round or ovoid, about 2-5 mm in diameter and are non-vascular. Foci larger than this, suggest more extensive damage and require careful follow up or monitoring. [11]



**Figure 5:** USG evaluation of Sialolith. [12]



**Figure 6:** USG examination of ranula.



**Figure 7:** USG evaluation of parotid salivary gland enlargement in patient with Sjögren's syndrome.

## Conclusion

There are many salivary gland imaging can be used including radiation and non-radiation imaging. Ultrasonography (USG) is a non-radiation imaging, inexpensive, and readily available imaging technique that can be used to make diagnosis of salivary gland disorder such as sialolithiasis, mucocele, ranula, and Sjögren's syndrome. As a dentist we can consider to use ultrasonography eventhough is still widely unknown but their benefit are rewarding.

## References

1. Fox PC and Ship JA. "Salivary Gland Disease in Burket's Oral Medicine. 11<sup>th</sup> edition". Hamilton: BC Decker Inc. (2008): 191-213.
2. Scully C. Oral and Maxillofacial Medicine, 2<sup>nd</sup> edition. Edinburgh: Churchill Livingstone Elsevier. (2008): 279-287.
3. Kumar S and Mahahob N. "Ultrasound in Dentistry-A Review". *Journal of Indian Academy of Dental Specialist Researchers* 1.4 (2010): 44-45.
4. Ghom AG. Textbook of Oral Medicine. 1st edition. New Delhi: Jaypee Brothers Medical Publishers (P) Ltd. (2005): 561-583.
5. Bradley and Lichius G. "Salivary Gland Disorders and Diseases: Diagnosis and Management". George Thieme Verlag KG (2011): 58-59.
6. Silverman S., et al. Essential of Oral Medicine. Hamilton: BC Decker Inc. (2002): 260-276.
7. Maljkovic V and Gaspirc B. "Case Report: Laser-Assisted Treatment of Sialolithiasis". *Journal of the Laser and Health Academy* 1 (2014): 45-46.
8. Shamim T. "Oral Mucocele (Mucous Extravasation Cyst)". *Journal of Ayub Medical College Abbottabad* 21.1 (2009): 169.
9. Singh BG., et al. "A Rare Case of Congenital Simple Cystic Ranula in a Neonate". *Case Reports in Otolaryngology* (2013): 1-3.
10. Hallur N., et al. "Management of Ranula". *International Journal of Dental Clinics* 3.3 (2011): 79-80.
11. Rout J. "Radiographic Diagnosis of Sjögren's syndrome". *British Sjögren's Syndrome Association* 24.4 (2009): 1-3.
12. Sindhar T and Gnanasundaran N. "Ultrasonographic Evaluation of Salivary Gland Enlargement: A Pilot Study". *International Journal of Dental Sciences and Research* 102 (2013): 28-35.
13. Sheiki M., et al. "Plunging Ranula of the Submandibular Area". *Dental Research Journal* 8. S1 (2011): 114-118.

**Submit your next manuscript to Scientia Ricerca Open Access and benefit from:**

- Prompt and fair double blinded peer review from experts
- Fast and efficient online submission
- Timely updates about your manuscript status
- Sharing Option: Social Networking Enabled
- Open access: articles available free online
- Global attainment for your research

Submit your manuscript at:

<https://scientiaricerca.com/submit-manuscript.php>